



Pierre Fajadet

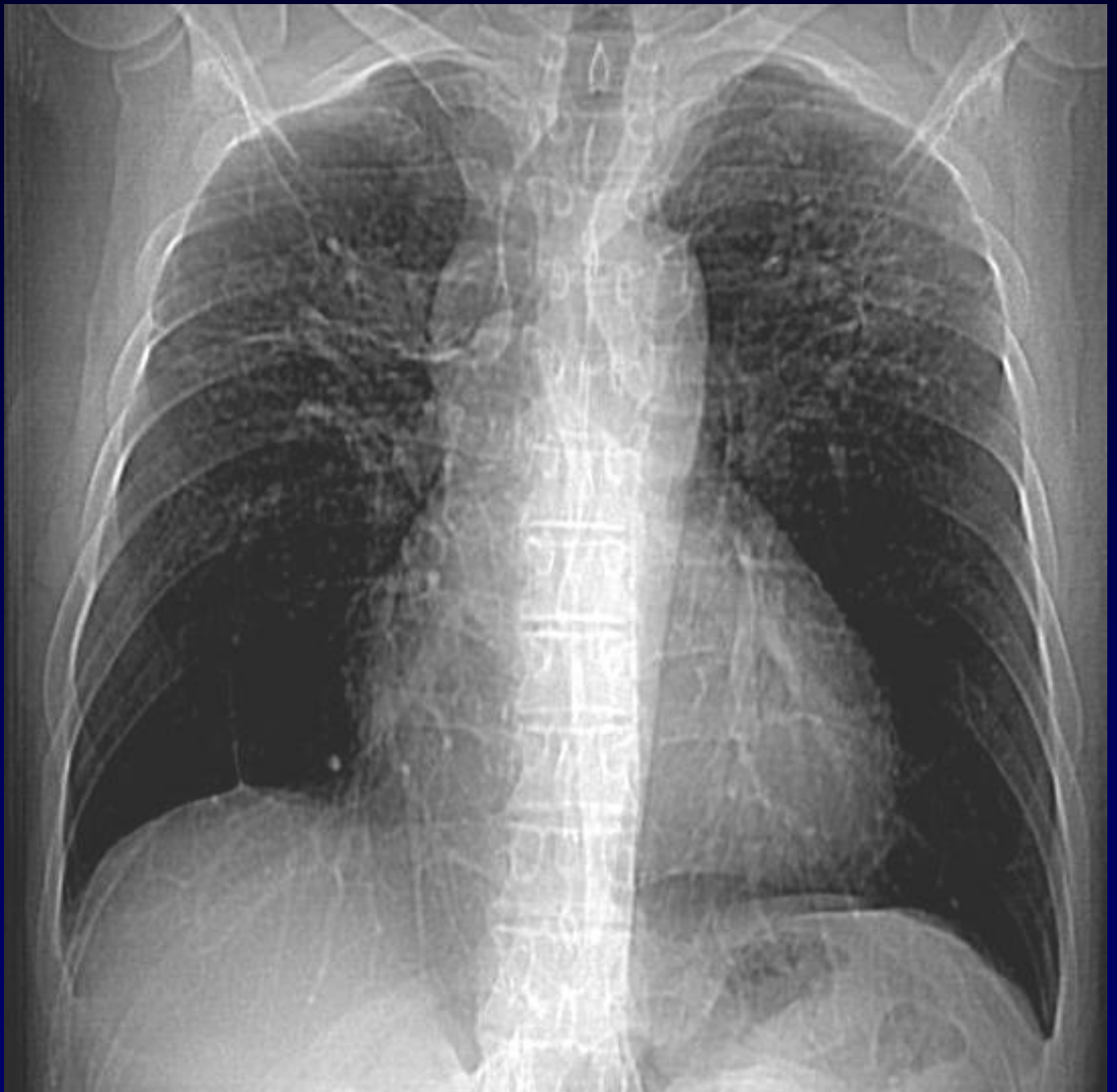
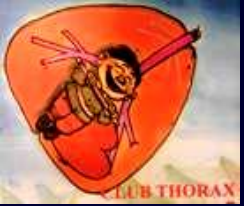Homme de 55 ans

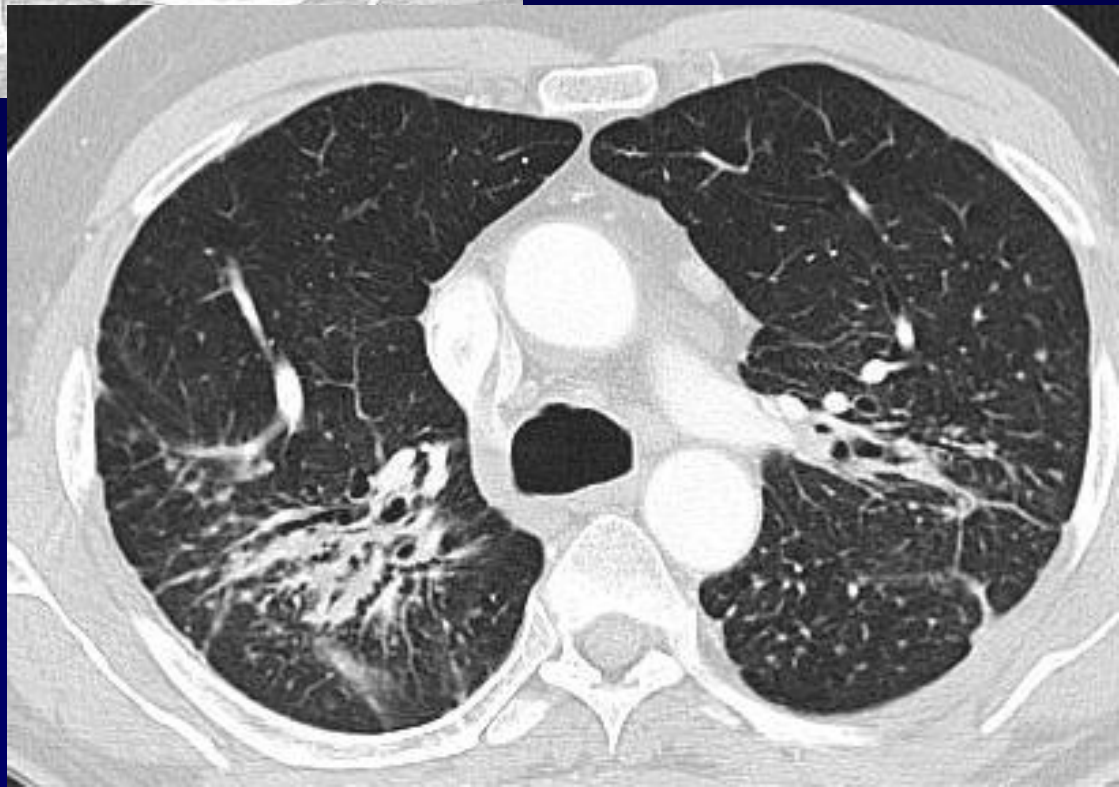
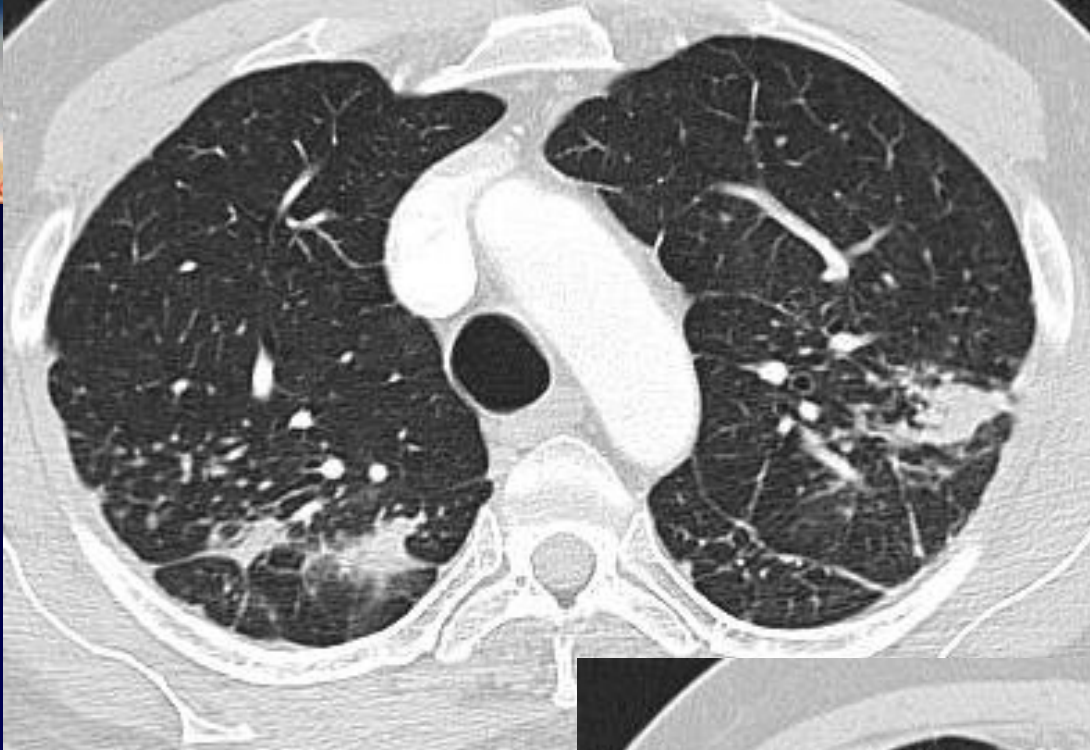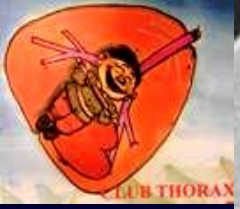ATCD = 0

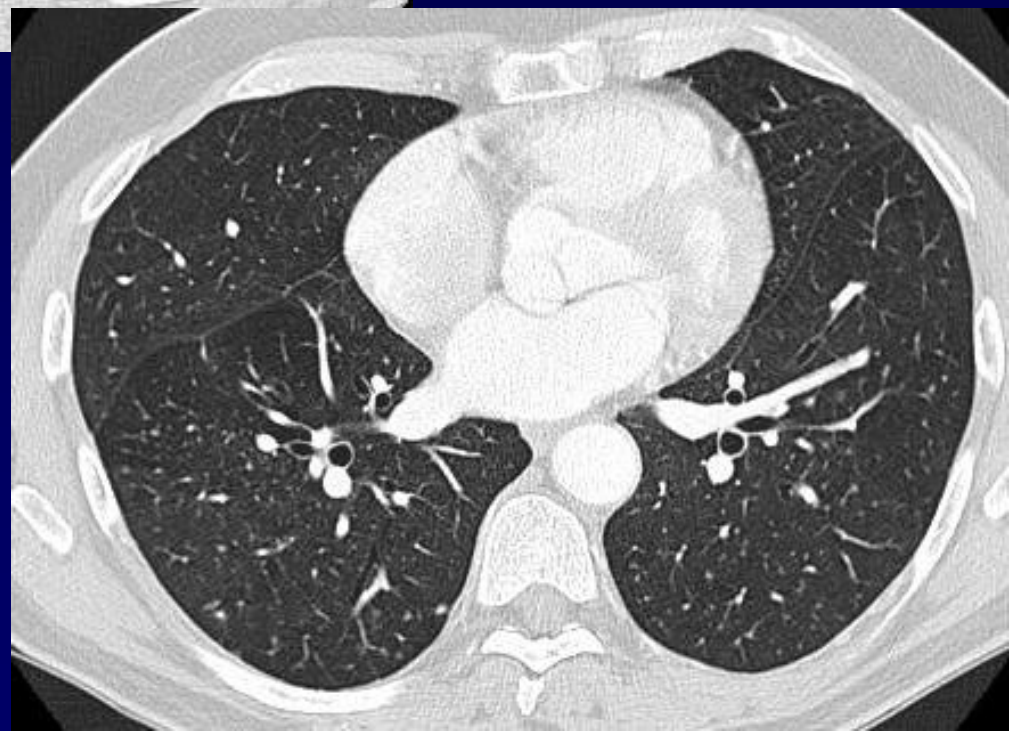
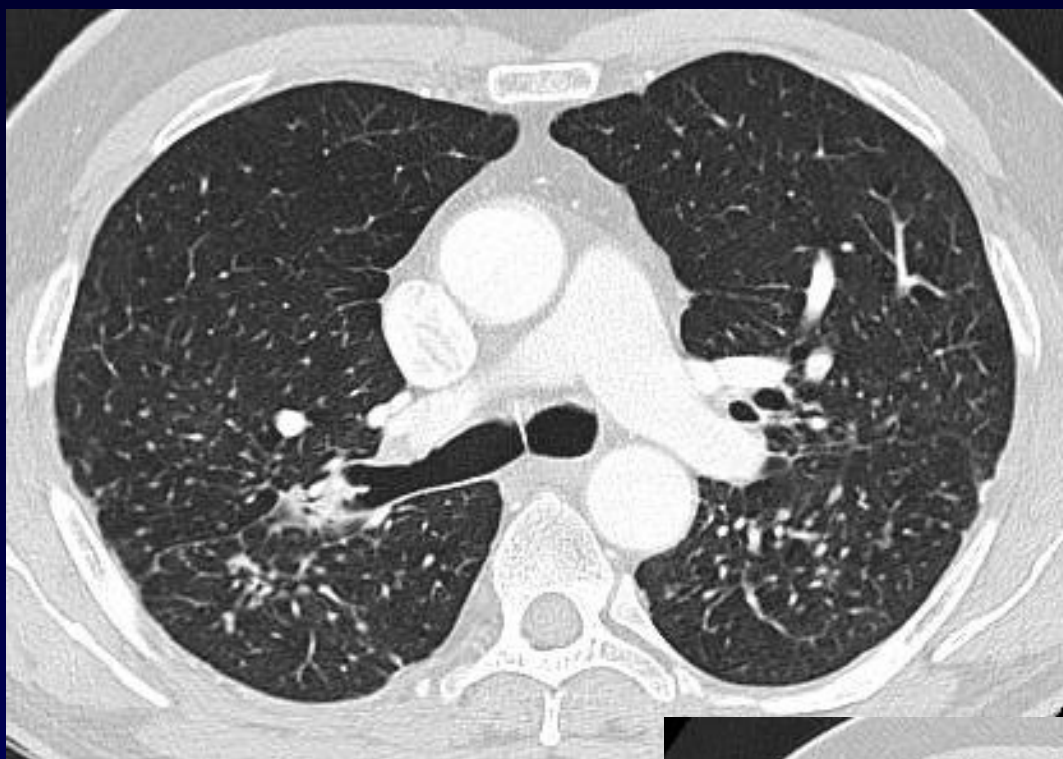
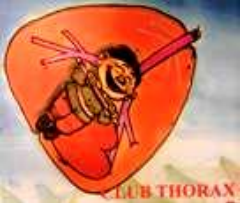dyspnée isolée

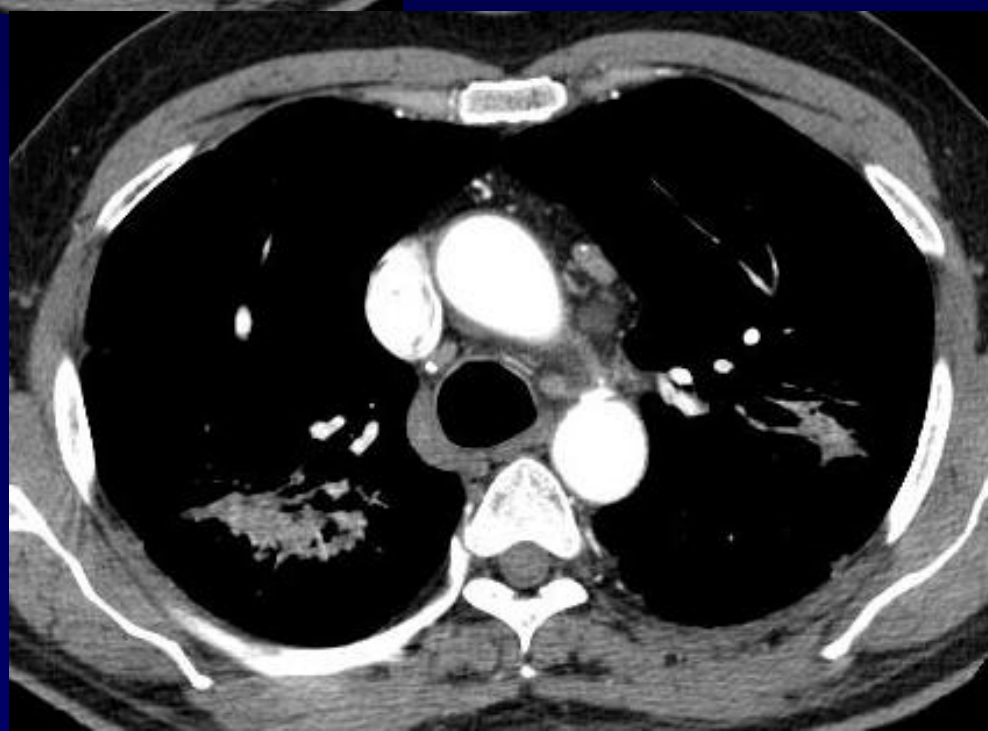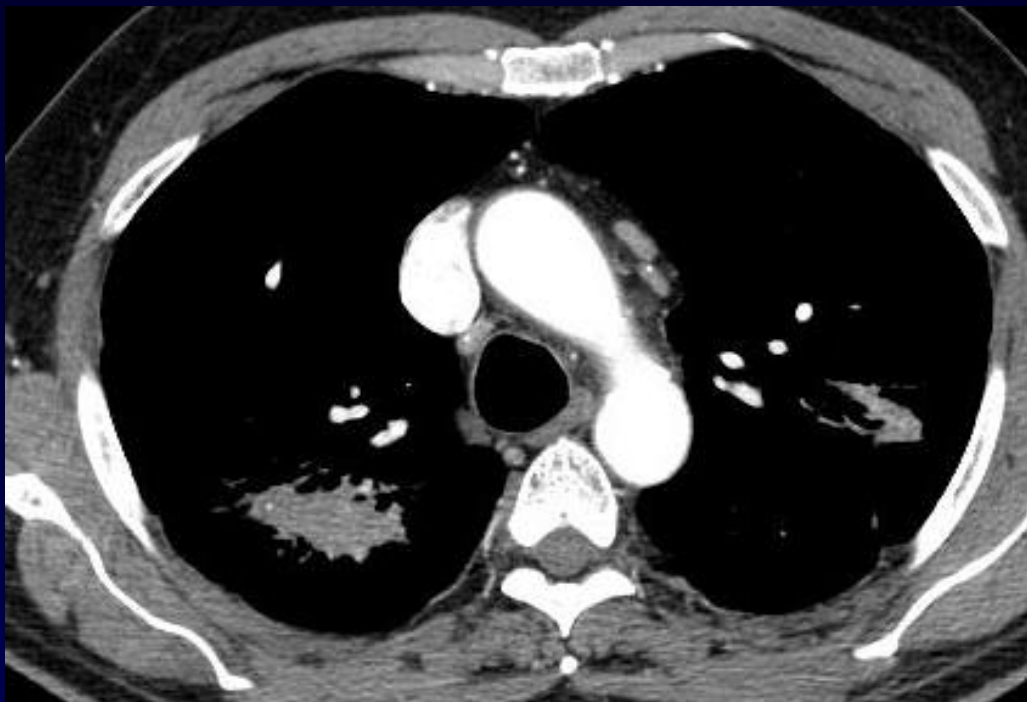Examen clinique normal

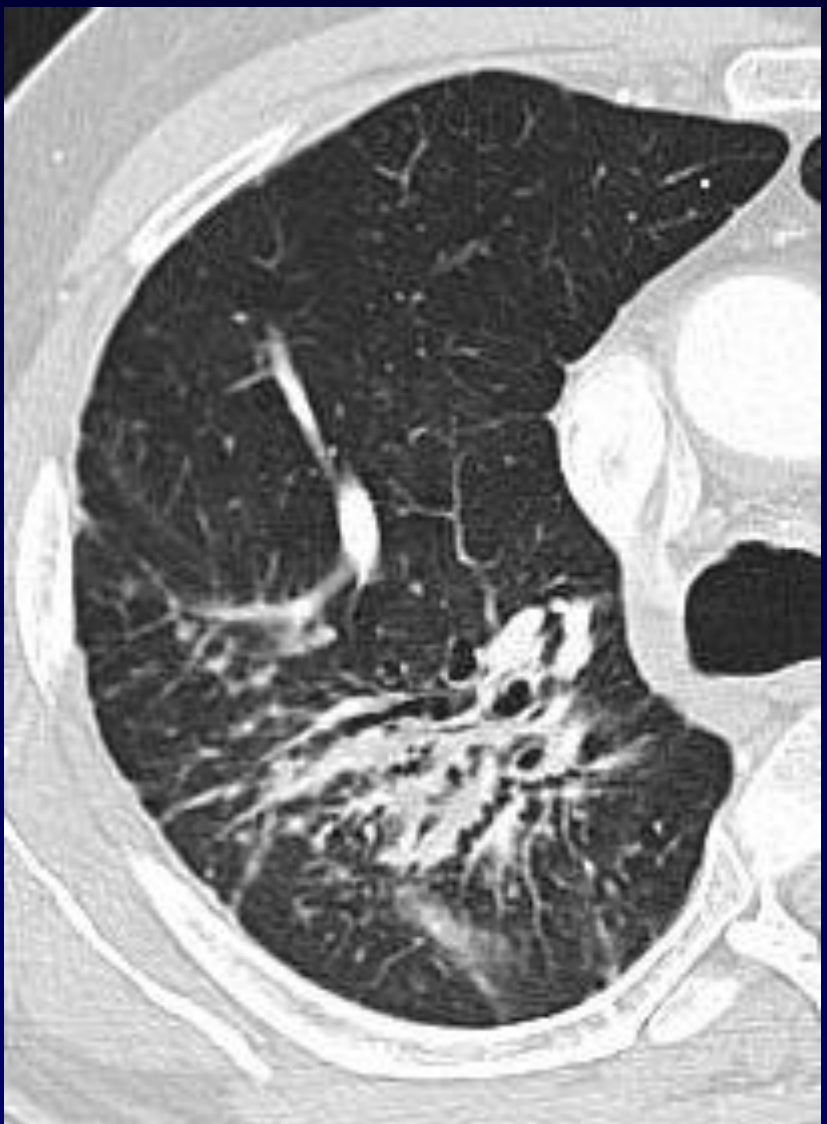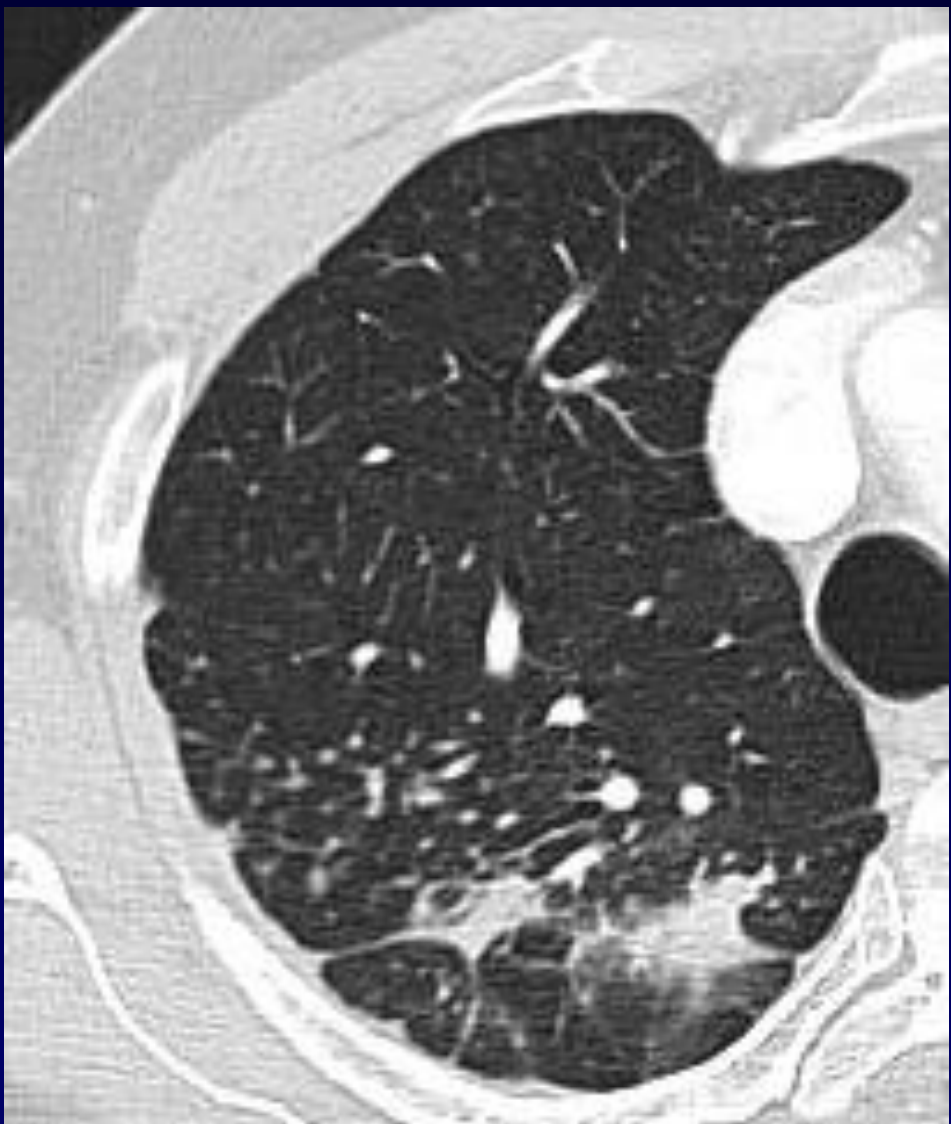EFR: Syndrome restrictif modéré





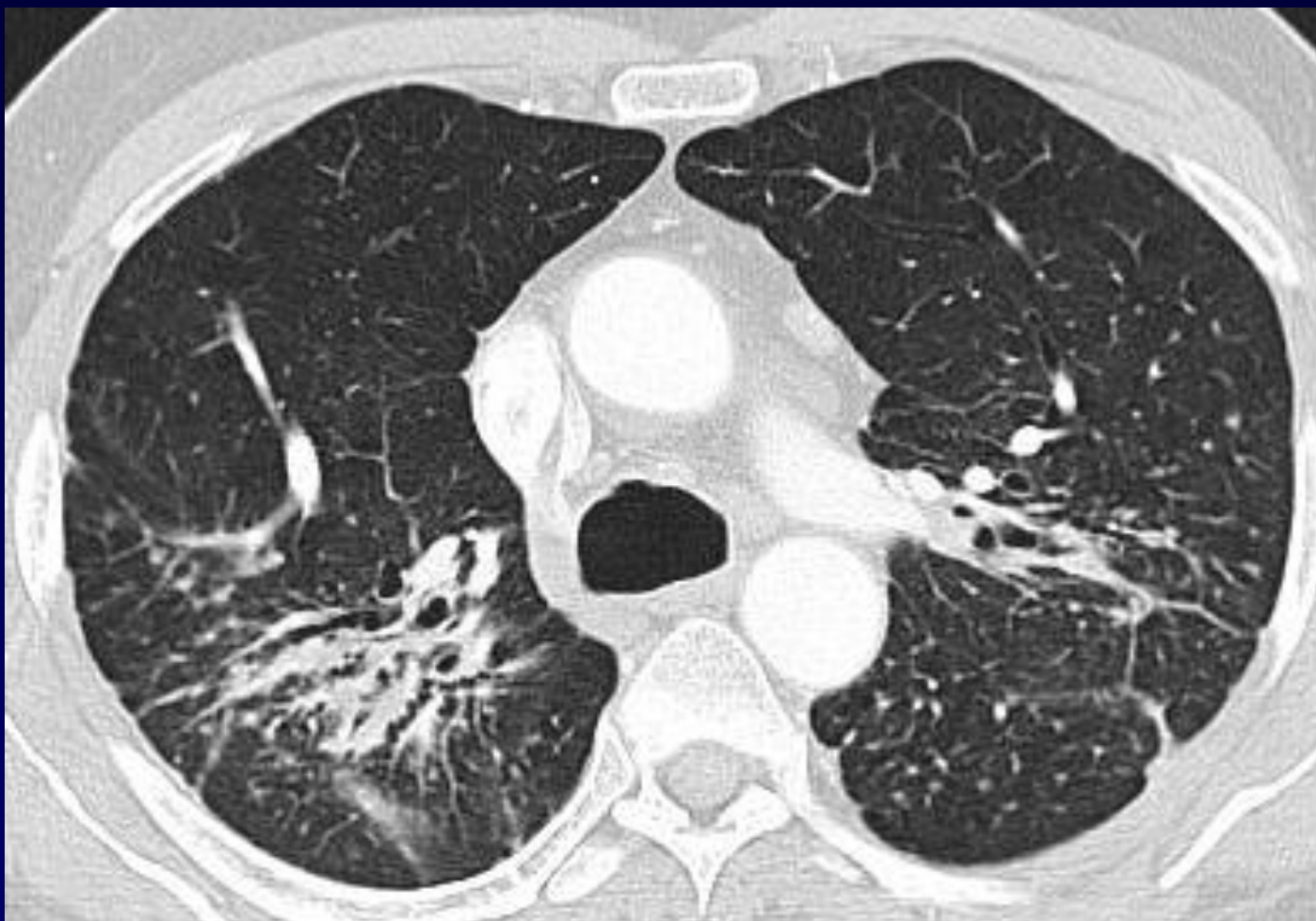







Diagnostic ?





Diagnostic

Silicose du prothésiste dentaire